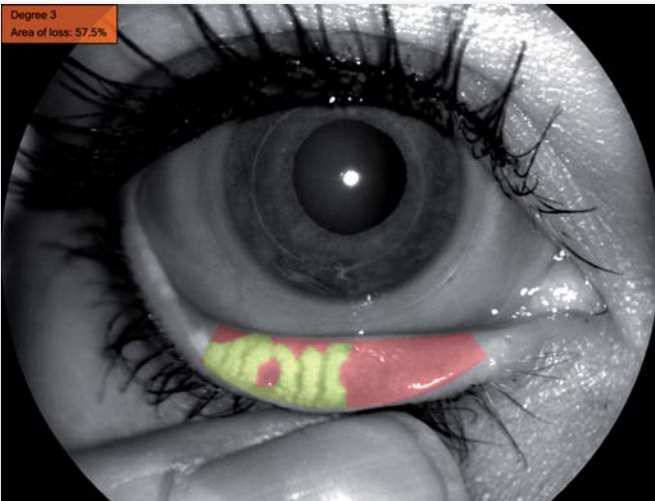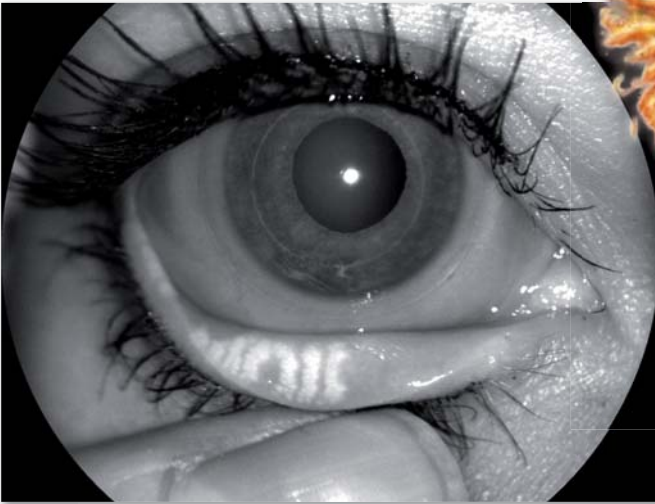


Meibography

With the Phoenix Analysis Software



- Quick and easy screening of evaporative dry eye.
- Patient Friendly “non contact” technique.
- Simple and precise digital classification of Meibomian Gland Dysfunction via the Phoenix software.
- The measurements can be carried out by the ophthalmic technician.

Up to 50% of contact lens wearers and 20% of patients who do not wear lenses complain of dry eye symptoms. 1-3.

The most common form of dry eye is “evaporative dry eye” and Meibomian Gland Dysfunction is widely acknowledged to be the main cause.⁴⁻⁶ A chronic dysfunction of the Meibomian glands, Blepharitis, computer screens, increasing age and contact lens wear can all lead to the degeneration and loss of the Meibomian glands.^{9, 10}

Meibography With the Phoenix Analysis Software

The **Sirius** Scheimpflugcamera, the **Cobra** Fundus Camera and the topographer **EyeTop-S** and **Antares** and can all be used in combination with the **Phoenix**-Meibography Imaging Module, to make a rapid and easy assessment of the Meibomian gland morphology. Irregularities can be quick and easily assessed.

The so called “ Non Contact Technique”^{11,12} of the Phoenix Meibography together with a high resolution infra-red camera allow image capture with optimal patient comfort.



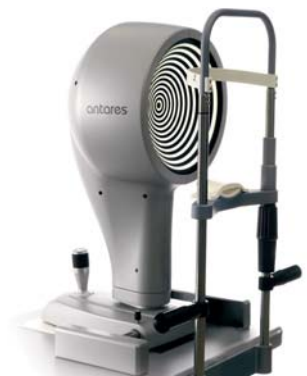SIRIUS
3D Scheimpflug-Camera
and Topography-System



COBRA
Nonmydriatic,
Digital Fundus Camera



EyeTop-S
Cornea-Topographer



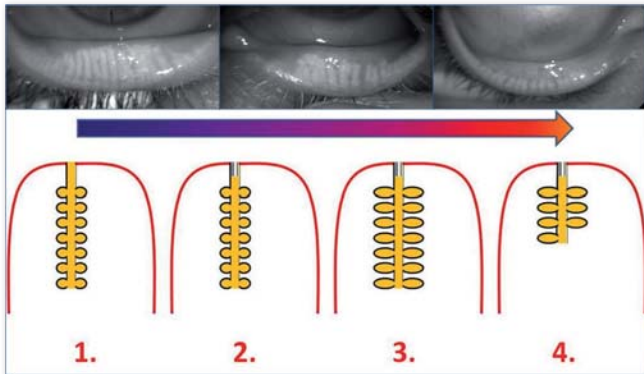
EyeTop-S
Tear Film-Topographer

Diagnosis of Meibomian Gland Dysfunction

Lid Morphology, the type of secretion during gland expression, the thickness of the lipid layer and gland loss are all factors of Meibomian Gland Dysfunction that can be assessed using Meibography.¹²⁻¹⁴

The unique in vivo imaging capability of the Phoenix Meibography module provides not only a true method for documenting change, it also enables you to distinguish between evaporative and aqueous tear deficient dry eye conditions.

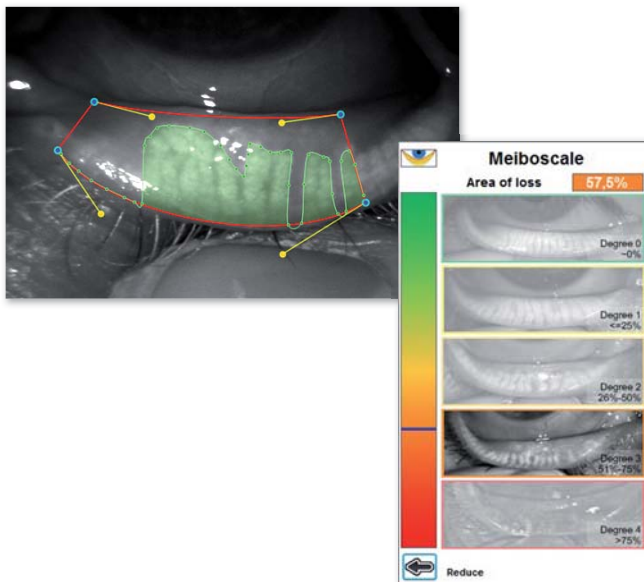
Exact diagnosis allows effective therapy.¹⁵



Beginning with (1) an elevated viscosity of the meibomian oil, due to a change in the melting point, an obstruction (2) of the meibomian gland opening occurs, resulting in hyper gland keratinization.

Stasis (3) increased pressure of the ductal system. Atrophy (4) of the gland acini, resulting in gland shortening and total gland loss.

Whereas stages (1) and (2) can be evaluated via gland expression at the slit lamp, stage (3) and (4) can otherwise not be assessed.



Classification:

The digital analysis ¹² of the Phoenix Meibography Module provides an exact and repeatable classification of the gland loss.

A surface loss of 30% indicates an evaporative dry eye.

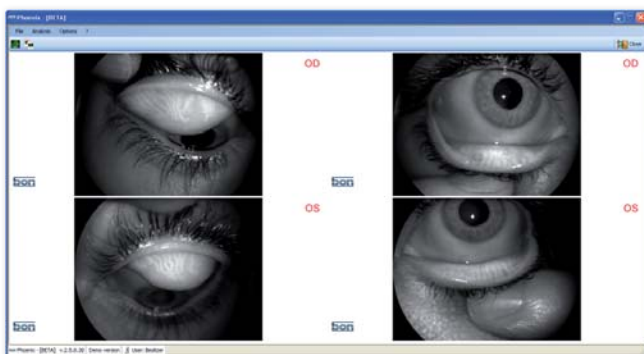
Phoenix Meibography is in all its applications (Scheimpflug, Topographer and Fundus Camera) extremely easy to use and can thus be delegated for quick and easy screening, saving chair time in the diagnosis and therapy of dry eye.

Documentation:

Phoenix Meibography provides excellent documentation possibilities allowing a clear overview for follow up and therapy planning purposes.

Phoenix Meibography is a must for the contact lens fitter, it provides a complete overview and allows specific monitoring of contact lens related gland loss.

The digital graphics make patient education easy and effective and help gain improved compliance and recall visits.



References:

1. Smith JA, Albeitz J, Begley C, Caffery B, Nichols K, Schaumberg D, Schein O. The epidemiology of dry eye disease: Report of the Epidemiology Subcommittee of the International Dry Eye WorkShop (2007). *Ocul Surf* 2007;5:93-107.
2. Pult H, Purslow C, Berry M, Murphy PJ. Clinical tests for successful contact lens wear: relationship and predictive potential. *Optom Vis Sci* 2008;85:E924-9.
3. Pult H, Purslow C, Murphy PJ. The relationship between clinical signs and dry eye symptoms. *Eye (Lond)* 2011;25:502-10.
4. Knop E, Knop N. Meibomian glands : part IV. Functional interactions in the pathogenesis of meibomian gland dysfunction (MGD). *Ophthalmologe* 2009;106:980-7.
5. Knop E, Knop N, Brewitt H, Pleyer U, Rieck P, Seitz B, Schirra F. Meibomian glands : part III. Dysfunction - argument for a discrete disease entity and as an important cause of dry eye. *Ophthalmologe* 2009;106:966-79.
6. Heiligenhaus A, Koch JM, Kruse FE, Schwarz C, Waubke TN. Diagnosis and differentiation of dry eye disorders. *Ophthalmologe* 1995;92:6-11.
7. Blackie CA, Korb DR, Knop E, Bedi R, Knop N, Holland EJ. Nonobvious Obstructive Meibomian Gland Dysfunction. *Cornea* 2010;29:1333-45.
8. Arita R, Itoh K, Inoue K, Kuchiba A, Yamaguchi T, Amano S. Contact Lens Wear Is Associated with Decrease of Meibomian Glands. *Ophthalmology* 2009;116:379-84.
9. Nichols KK, Foulks GN, Bron AJ, Glasgow BJ, Dogru M, Tsubota K, Lemp MA, Sullivan DA. The International Workshop on Meibomian Gland Dysfunction: Executive Summary. *Invest Ophthalmol Vis Sci* 2011;52:1922-9.
10. Pult H. Dry eye in soft contact lens wearers. *Contact Lens Spectrum* 2011;07:26-53.
11. Arita R, Itoh K, Inoue K, Amano S. Noncontact infrared meibography to document age-related changes of the meibomian glands in a normal population. *Ophthalmology* 2008;115:911-5.
12. Pult H, Riede-Pult BH. Non-contact meibography: Keep it simple but effective. *Contact Lens and Anterior Eye* 2011;In Press, Corrected Proof.
13. Nelson JD, Shimazaki J, Benitez-del-Castillo JM, Craig JP, McCulley JP, Den S, Foulks GN. The International Workshop on Meibomian Gland Dysfunction: Report of the Definition and Classification Subcommittee. *Investigative Ophthalmology & Visual Science* 2011;52:1930-7.
14. Blackie CA, Korb DR. Meibomian Gland Expression: Forces of Expression, Types of Secretion and the Limitation of Resulting Pain. *Investigative Ophthalmology & Visual Science* 2010;51:3385-.
15. Geerling G, Tauber J, Baudouin C, Goto E, Matsumoto Y, O'Brien T, Rolando M, Tsubota K, Nichols KK. The International Workshop on Meibomian Gland Dysfunction: Report of the Subcommittee on Management and Treatment of Meibomian Gland Dysfunction. *Investigative Ophthalmology & Visual Science* 2011;52:2050-64.