

Intraoperative and Postoperative Effects of Corneal Collagen Cross-linking on Progressive Keratoconus

Paolo Vinciguerra, MD; Elena Albè, MD; Silvia Trazza, BS; Theo Seiler, MD; Daniel Epstein, MD, PhD

Objectives: To report intraoperative and 24-month refractive, topographic, tomographic, and aberrometric outcomes after corneal collagen cross-linking in progressive advanced keratoconus.

Methods: Prospective, nonrandomized single-center clinical study involving 28 eyes. Main outcome measures included uncorrected and best spectacle-corrected visual acuities, sphere and cylinder refraction, topography, tomography, aberrometry, and endothelial cell count evaluated at baseline and follow-up at 1, 3, 6, 12, and 24 months after treatment. Topography was also recorded intraoperatively.

Results: Two years after treatment, mean baseline uncorrected and best spectacle-corrected visual acuities improved significantly ($P = .048$ and $< .001$, respectively) and mean spherical equivalent refraction decreased significantly ($P = .03$). Mean baseline flattest and steepest me-

ridians on simulated keratometry, simulated keratometry average, mean average pupillary power, and apical keratometry all decreased significantly ($P < .03$). Deterioration of the Klyce indices was observed in the untreated contralateral eyes but not in treated eyes. Total corneal wavefront aberrations Z_0 (piston), Z_2 (defocus), and Z_7 (III coma) decreased significantly ($P \leq .046$). Mean 12-month baseline pupil center pachymetry and total corneal volume decreased significantly ($P = .045$). Endothelial cell counts did not change significantly ($P = .13$).

Conclusions: Two years postoperatively, corneal collagen cross-linking appears to be effective in improving uncorrected and best spectacle-corrected visual acuities in eyes with progressive keratoconus by significantly reducing corneal average pupillary power, apical keratometry, and total corneal wavefront aberrations.

Arch Ophthalmol. 2009;127(10):1258-1265

A NEW TREATMENT, UV CORNEAL collagen cross-linking (CXL), has been recently introduced to reduce the progression of noninflammatory corneal degeneration such as keratoconus, pellucid marginal degeneration, and ectatic corneal disorders after corneal refractive procedures.¹⁻³ The treatment consists of CXL by the photosensitizer riboflavin and UV-A light preceded by corneal epithelial removal.⁴

Since the early 1990s, basic laboratory studies have demonstrated that CXL caused a long-term increase in corneal biomechanical rigidity by stiffening the human cornea by more than 300%,³ increasing the collagen fiber diameter by 12.2%,⁶ and inducing the formation of high-molecular-weight collagen polymers, with a remarkable chemical stability.⁷ Subsequent clinical studies have shown the safety and efficacy of the procedure in reducing the deterioration of normally progressive corneal disorders.^{3,8}

However, an intraoperative and postoperative topographic analysis of CXL ef-

fects on keratoconic corneas has not yet been performed. In this study we examined corneal topographic changes during the CXL procedure and refractive, topographic, tomographic, and aberrometric outcomes 24 months after CXL in eyes with progressive stage III keratoconus (Amsler-Krumeich classification).⁹⁻¹²

METHODS

POPULATION

Twenty-eight eyes of 28 patients (8 women and 20 men) in whom keratoconus progression in 1 eye was documented in the preceding 6 months were enrolled in this prospective nonrandomized, single-center study. We also observed the contralateral keratoconic eyes and compared the corneal variables with those of the treated eyes.

Preoperative keratoconus progression was confirmed by serial differential corneal topography and by differential optical pachymetry analysis in all eyes included in the study.¹³ The Amsler-Krumeich classification was used for keratoconus grading.⁹⁻¹² Inclusion criteria were documented keratoconus progression in the

Author Affiliations:
Department of Ophthalmology, Istituto Clinico Humanitas, Milano, Italy (Drs Vinciguerra and Albè and Ms Trazza); and IROC (Institute for Refractive and Ophthalmic Surgery) (Dr Seiler) and Department of Ophthalmology, University Hospital Zurich (Dr Epstein), Zurich, Switzerland.

previous 6 months, corneal thickness of at least 400 μm at the thinnest point, and age 18 to 60 years.

The age of the patients included in the study ranged from 24 to 52 years. Of the treated eyes, 8 were right and 20 were left eyes. Keratoconus in all treated eyes was graded as stage III according to the Amsler-Krumeich classification. Keratoconus in the untreated contralateral eyes was graded as stages I and II.

Exclusion criteria included corneal thickness of less than 400 μm at the thinnest point,^{5,14-17} pregnancy, and a history of herpetic keratitis, severe eye dry, concurrent corneal infections, concomitant autoimmune diseases, or any ocular surgery. The study received institutional review board approval by the ethical committee of Istituto Clinico Humanitas and was conducted according to the ethical standards set in the 1964 Declaration of Helsinki, as revised in 2000. All patients signed an informed consent form.

Corneal topography was performed in all treated eyes before epithelial scraping and immediately after epithelial debridement. At baseline and at each of the postoperative follow-up examinations (1, 3, 6, 12, and 24 months after treatment), all patients underwent the examinations described in the following section.

EXAMINATIONS

Visual acuity was assessed with the Early Treatment Diabetic Retinopathy Study logMAR charts (Lighthouse International, New York, New York).¹⁸⁻²⁰ Measurements were made with best correction after a noncycloplegic refraction at 4 m.

Corneal topography was performed with a commercially available corneal topographer (CSO EyeTop Topographer; Compagnia Strumenti Oftalmici, Florence, Italy). The corneal topographer analyzes 6144 points (24 rings each with 256 radial spots) across a 9.5-mm² corneal surface area. Repeatability is ± 0.03 mm for axial and instantaneous maps and ± 0.5 μm for elevation maps. The sensitivity of the technique for keratoconus detection is 98.5%.²¹ A refractive surgery platform (OPD-Scan, Optical Path Difference Platform; NIDEK Co Ltd, Gamagori, Japan) was also used to supply data on topography by means of the 21 Klyce indices provided by the manufacturer's classifier corneal topography map (Corneal Navigator TopoClassifier Map; NIDEK Co Ltd).²²⁻²⁷

We evaluated corneal lower- and higher-order aberrations to the seventh order for a 7-mm pupil using a corneal aberrometry program (CSO EyeTop Topographer).

We performed an anterior chamber analysis with optical tomography (Pentacam HR scanner; Oculus Inc, Lynnwood, Washington), a reliable tool for imaging and measuring the anterior segment of the eye using a rotating Scheimpflug camera.²⁶⁻³⁰ Ambrósio indices were also evaluated to classify different stages of keratoconus with respect to volume calculations and corneal thickness measurements across the entire cornea.³¹

We performed endothelial biomicroscopy using a specular microscope (Konan Medical Inc, Hyogo, Japan) according to the method described by Prinz et al.³²

CXL PROCEDURE

All patients underwent CXL as a day-surgery procedure. Analgesic medication was administered 30 minutes before the procedure. Pilocarpine drops, 2%, were instilled in the eye to be treated to reduce the amount of light rays potentially harmful to the lens and retina.

The procedure was conducted under sterile conditions in the operating suite. After topical anesthesia with 2 applica-

tions of lidocaine hydrochloride drops, 4%, and benoxinate hydrochloride (oxybuprocaine hydrochloride), 0.2%, the corneal epithelium was abraded in a central, 9-mm-diameter area with the aid of an Amoil brush.

Before beginning UV-A irradiation, photosensitizing riboflavin in a 0.1% solution (10 mg of riboflavin 5'-phosphate in a 20% dextran T-500 10-mL solution [Ricola; SOOFT Italia SRL, Montegiorgio, Italy]) was applied to the cornea every minute for 30 minutes to achieve adequate penetration of the solution. Using a slitlamp with the blue filter, the surgeon (P.V.) confirmed the presence of riboflavin in the anterior chamber before UV-A irradiation was started. The cornea was exposed to a UV source emanating from a solid-state device (UV-X System; Peschke Meditrade GmbH, Huenenberg, Switzerland) that emits light at a mean (SD) wavelength of 370 (5) nm and an irradiance of 3 mW/cm² or 5.4 J/cm². Exposure lasted for 30 minutes, during which time the riboflavin solution was again applied, but only once every 5 minutes. The cropped light beam has a 5- to 7-mm diameter. A calibrated UV-A meter (Laser-Mate-Q; Laser 2000 GmbH, Wessling, Germany) was used before treatment to check the irradiance at a 5-cm distance.

Postoperatively, patients received cyclopentolate hydrochloride and levofloxacin drops. A bandage soft contact lens was applied until reepithelialization was complete. Topical levofloxacin was given 4 times daily for 7 days; dexamethasone 21-phosphate drops, 0.15%, 3 times daily for 20 days; and hyaluronate sodium drops, 0.15%, 6 times daily for 45 days. In addition, all patients received oral amino acid supplements for 7 days.³³ The mean (SD) reepithelialization time was 46 (11) hours. All patients were followed up for 24 months.

DATA ANALYSIS

Statistical analyses were performed with a commercially available computer software package (Statistica; StatSoft Inc, Tulsa, Oklahoma). All data are reported as mean (SD). The normality of the data was tested using the Kolmogorov-Smirnov test and the normal probability plot. The paired *t* test was used to check the significance of the difference between 2 dependent groups. The level of statistical significance was set at $P < .05$.

RESULTS

VISUAL ACUITY RESULTS

The uncorrected and best spectacle-corrected visual acuity (VA) data, expressed in logMAR units and covering the entire follow-up period, are summarized in **Table 1**. Improvement in uncorrected and best spectacle-corrected VA was statistically significant ($P = .048$ and $P < .001$, respectively) when we compared the preoperative with the postoperative data 24 months after CXL.

REFRACTIVE RESULTS

The mean preoperative spherical equivalent was -3.37 (2.64) diopters (D), with a mean sphere of -1.86 (2.58) D and a mean cylinder of -3.02 (1.74) D. Two years after CXL, the mean spherical equivalent was -2.56 (2.68) D; mean sphere, -1.22 (1.65) D; and mean cylinder, -2.68 (1.12) D. The differences in preoperative and 24-month postoperative mean sphere and mean cylinder were statistically significant ($P = .03$). Vector analysis showed an

Table 1. Uncorrected and Best Spectacle-Corrected VA in 28 Treated Eyes Before and After CXL^a

VA	Pre-CXL	Postoperative Follow-up, mo				
		1	3	6	12	24
Uncorrected	0.77 (0.18)	0.62 (0.20)	0.55 (0.21)	0.51 (0.22)	0.57 (0.16)	0.53 (0.19)
Best spectacle-corrected	0.28 (0.09)	0.25 (0.10)	0.17 (0.11)	0.17 (0.08)	0.14 (0.08)	0.13 (0.10)

Abbreviations: CXL, corneal collagen cross-linking; VA, visual acuity.
^aData are expressed as mean (SD) logMAR units.

Table 2. Topographic Astigmatism as Measured With a Corneal Topographer^a

Measurement	Pre-CXL With Epithelium	Pre-CXL Without Epithelium	Postoperative Follow-up, mo					P Value ^b	
			1	3	6	12	24	Pre-CXL With and Pre-CXL Without Epithelium	Pre-CXL ^c and 24-mo Follow-up
Simulated keratometry, D									
Flattest meridian	46.10	47.49	46.56	46.30	45.45	45.44	45.43	.17	.049
Steepest meridian	50.37	53.59	51.62	50.86	49.89	49.58	49.02	.03	.03
Average	48.08	50.26	48.87	48.37	47.52	47.01	46.97	.06	.03
Cylinder	-4.27	-6.10	-5.06	-4.56	-4.44	-3.99	-3.80	.01	.03
Keratometry reading, D									
3 mm	-4.73	-5.35	-4.96	-4.94	-4.69	-4.19	-4.15	.39	.41
5 mm	-3.64	-4.36	-3.92	-3.68	-3.60	-3.27	-3.25	.21	.57

Abbreviations: CXL, corneal collagen cross-linking; D, diopters.
^aPerformed with the CSO EyeTop Topographer (Compagnia Strumenti Oftalmici, Florence, Italy).
^bSignificant differences are indicated in boldface.
^cIndicates obtained with and without the epithelium intact.

axis shift from 93.15 (43.26) D to 100 (38.01) D after CXL ($P = .64$).

TOPOGRAPHIC RESULTS

Topographic astigmatism measured with the corneal topographer during follow-up is shown in **Table 2**. The mean baseline flattest meridian keratometry, steepest meridian keratometry, and average keratometry were 46.10, 50.37, and 48.08 D, respectively. Twenty-four months after treatment, these readings were 45.43, 49.02, and 46.97 D, respectively, differences that were statistically significant for all 3 variables ($P \leq .04$).

Table 3 lists keratoconus indices obtained with the corneal topographer during follow-up. Mean baseline average pupillary power, apical keratometry, apical gradient curvature, inferior-superior symmetry index, and cone surface area were 47.50, 58.94, and 8.41 D and 11.66 and 9.53 mm², respectively. Twenty-four months after CXL, these indices were 46.76, 57.36, and 7.86 D and 10.43 and 8.75 mm², respectively. All 5 indices were significantly lower ($P \leq .04$) 24 months postoperatively, showing a flattening effect on the keratoconic cornea. Twenty-four months after CXL, the flattest meridian keratometry showed a mean reduction of 0.49 D, whereas the steepest meridian keratometry showed a mean reduction of 1.19 D. Average pupillary power and apical keratometry showed mean reductions of 0.68 and 1.06 D, respectively.

The mean baseline steepest meridian keratometry, simulated cylinder, and apical keratometry measurements were 46.10, -4.27, and 58.94 D, respectively.

After epithelial debridement these measured 53.59, -6.10, and 61.45 D, respectively, differences that were statistically significant for all 3 variables ($P < .05$). As apparent from the data in Tables 2 and 3, topographic astigmatism significantly increased immediately after epithelial removal (before UV-A irradiation was initiated) but decreased during the first 6 postoperative months.

The advanced elevation map obtained with the corneal topographer showed a statistically significant flattening of the keratoconus apex of 11 μm between the preoperative anterior elevation map taken immediately after epithelial scraping and the postoperative anterior elevation map 1 month later ($P = .04$). Instantaneous map comparisons of the steepest point of the anterior surface curvature showed a mean change from 58.82 D before epithelial removal to 61.05 D after scraping and to 60.54 D 1 month after CXL. The flattest point of the anterior surface curvature before epithelial debridement, after scraping, and 1 month after CXL showed a mean change from 36.44 D to 32.77 to 34.12 D, respectively. None of these differences was statistically significant.

Klyce indices obtained with the refractive surgery platform were analyzed in treated and untreated eyes at baseline and 12 and 24 months after CXL. Preoperative differences between the 2 groups with respect to the indices were statistically significant, as shown in **Table 4**. Twenty-four months after CXL, several of the Klyce indices of the treated eyes had significantly decreased ($P < .05$). In contrast, several of the Klyce indices of the

Table 3. Changes in Keratoconus Indices Documented With the Corneal Topographer^a

Measurement	Pre-CXL With Epithelium	Pre-CXL Without Epithelium	Postoperative Follow-up, mo					P Value ^b	
			1	3	6	12	24	Pre-CXL With and Without Epithelium	Pre-CXL ^c and 24-mo Follow-up
Keratometry average pupillary power, D	47.50	49.41	48.34	47.99	47.09	46.89	46.76	.07	.04
Keratoconus									
Apical keratometry, D	58.94	61.45	60.08	59.40	58.83	58.20	57.36	.048	.048
Apical gradient curvature, D	8.41	9.69	9.22	8.85	8.74	8.30	7.86	.14	.04
Inferior-superior symmetry index, mm ²	11.66	13.67	12.10	11.17	10.86	10.72	10.43	.19	.04
Circular factor	1.27	1.40	1.16	1.20	1.26	1.27	1.28	.17	.44
Surface area, mm ²	9.53	9.89	9.30	9.50	8.86	8.82	8.75	.71	.02
Perimeter, mm	12.16	13.07	11.56	11.83	11.68	11.59	11.48	.31	.28

Abbreviations: CXL, corneal collagen cross-linking; D, diopters.

^aPerformed with the CSO EyeTop Topographer (Compagnia Strumenti Oftalmici, Florence, Italy).

^bSignificant differences are indicated in boldface.

^cIndicates obtained with and without the epithelium intact.

Table 4. Changes in Klyce Indices Measured With the Refractive Surgery Platform^a

Klyce Index	Treated Eye			Untreated Eye		
	Pre-CXL	12-mo Follow-up	24-mo Follow-up	Pre-CXL	12-mo Follow-up	24-mo Follow-up
Average corneal power, D	49.61	49.23 ^b	46.77 ^{b,c}	44.80	45.33 ^d	45.31 ^{c,d}
Simulated keratometry cylinder	4.62	4.27 ^b	4.30 ^{b,c}	2.49	2.64 ^d	2.74 ^{c,d}
Coefficient of variation of corneal power	104.78	102.96 ^b	102.75 ^{b,c}	59.99	64.15 ^d	70.01 ^{c,d}
Standard deviation of corneal power	5.07	4.96 ^b	5.05 ^b	2.77	2.94 ^d	3.19 ^{c,d}
Analyzed area, %	81.18	81.64 ^d	83.42 ^{c,d}	81.48	82.30 ^d	84.07 ^{c,d}
Corneal eccentricity index	1.13	1.09 ^b	1.08 ^{b,c}	0.36	0.54 ^d	0.54 ^{c,d}
LogMAR	0.26	0.25 ^b	0.25 ^b	0.10	0.11 ^d	0.13 ^d
Differential sector index	13.18	12.88 ^b	12.77 ^{b,c}	7.90	8.31 ^d	8.95 ^{c,d}
Surface regularity index	1.64	1.61 ^b	1.62 ^b	1.13	1.17 ^d	1.27 ^{c,d}
Area-compensated surface regularity index	1.47	1.45 ^b	1.44 ^b	1.05	1.06 ^d	1.08 ^d
Surface asymmetry index	3.02	2.83 ^b	3.02 ^e	1.69	1.78 ^d	2.05 ^{c,d}
Irregular astigmatism index	0.62	0.62 ^e	0.59 ^b	0.53	0.53 ^e	0.52 ^d
Opposite sector index	10.61	10.46 ^b	10.48 ^{b,c}	6.24	6.57 ^d	7.24 ^{c,d}
Center surround index	3.08	2.92 ^b	2.81 ^{b,c}	0.73	1.02 ^d	1.07 ^{c,d}
Keratoconus index	0.90	0.88 ^b	1.00 ^d	0.44	0.45 ^d	1.00 ^{c,d}
Keratoconus prediction index	0.44	0.43 ^b	0.44 ^e	0.35	0.31 ^d	0.33 ^b
Elevation/depression power, D	4.23	3.84 ^b	4.04 ^{b,c}	2.31	2.36 ^d	2.58 ^{c,d}
Elevation/depression diameter, mm	16.40	16.24 ^b	17.35 ^d	9.09	9.43 ^d	11.12 ^{c,d}

Abbreviations: CXL, corneal collagen cross-linking; D, diopters.

^aObtained using the Optical Path Difference Platform (NIDEK Co Ltd, Gamagori, Japan).

^bIndicates decreased values at the 12- and 24-month follow-up examinations.

^cIndicates statistically significant differences for the 24-month follow-up, calculated using the paired *t* test for dependent data.

^dIndicates increased values at the 12- and 24-month follow-up examinations.

^eIndicates unchanged values at the 12- and 24-month follow-up examinations.

untreated eyes had significantly increased ($P < .05$) at the 2-year examination.

ABERROMETRIC RESULTS

Corneal higher-order aberrations for a 7-mm pupil were measured preoperatively and 24 months after CXL using the corneal aberrometry program. The results are shown in **Table 5**.

The total root mean square significantly decreased from 28.85 (3.21) to 25.2 (2.87) μm ($P = .047$), with a consistent reduction in all corneal aberrations up to the seventh order and a statistically significant reduction in Z_0 (piston) ($P = .04$), Z_2 (defocus) ($P = .046$), and Z_7 (III coma) ($P = .04$).

TOMOGRAPHIC RESULTS

Mean baseline pupil center pachymetry and total corneal volume measured with the optical tomographer were 490.68 (30.69) μm and 59.37 (4.36) mm^3 , respectively. Twelve months after CXL, they had decreased to 470.09 (29.01) μm and 57.17 (3.21) mm^3 , respectively, differences that were statistically significant ($P = .045$). These values rose to 479.91 (32.21) μm and 58.28 (4.21) mm^3 , respectively, 24 months after treatment ($P = .06$ compared with the 12-month values).

Partial corneal volumes at 3, 5, and 7 mm were also significantly reduced from 3.53 (0.20), 10.7 (0.57), and 23.73 (1.41) mm^3 , respectively, at baseline to 3.40 (0.17)

Table 5. Total and Single Corneal Aberrations Up to the Seventh Order Measured for a 7-mm Pupil Using the Corneal Aberrometry Program^a

Measured Area, RMS μm	Pre-CXL	24-mo Follow-up
Total ^b	28.85	25.2 ^c
Z ₀ (piston)	-13.17	-4.35 ^c
Z ₁ (tilt)	22.95	20.17
Z ₂ (astigmatism)	3.12	3.02
Z ₂ (defocus)	-8.06	-1.85 ^c
Z ₃ (trefoil)	0.98	0.91
Z ₃ (coma)	4.83	4.71 ^c
Z ₄ (quadrafoil)	0.41	0.31
Z ₄ (II astigmatism)	1.19	0.99 ^c
Z ₄ (spherical aberration)	-0.34	-0.25 ^c
Z ₅ (II coma)	0.87	0.73 ^c
Z ₆ (II spherical aberration)	0.01	0.17
Z ₇ (III coma)	0.24	0.15 ^c

Abbreviations: CXL, corneal collagen cross-linking; RMS, root mean square; Z, Zernicke order.

^aPerformed with the CSO EyeTop Topographer (Compagnia Strumenti Oftalmici, Florence, Italy).

^bThe total differs from the sum of the remaining rows because our study did not take into account aberrations beyond Z₇.

^cIndicates statistically significant differences for the 24-month follow-up examination, calculated using the paired *t* test for dependent data.

($P = .047$), 10.35 (0.44) ($P = .048$), and 22.86 (1.01) mm³ ($P = .04$), respectively, 12 months after CXL. However, 24 months after CXL, although the partial corneal volume at 3 mm (3.47 [0.12] mm³) was still significantly lower than that measured preoperatively, the partial corneal volumes at 5 and 7 mm (10.58 [0.89] and 23.27 [1.34] mm³, respectively) were not statistically different from the preoperative values.

Corneal pachymetry at the thinnest point decreased from baseline values of 451.14 (25.97) to 436.23 (29.38) μm 1 year after CXL ($P = .04$). It increased to recover at 443.04 (27.81) μm 24 months postoperatively ($P = .71$). Anterior chamber volume and anterior and posterior elevation did not change significantly during the 24-month follow-up.

Anterior chamber depth decreased from 3.42 (0.15) to 3.15 (0.06) mm 24 months postoperatively, a difference that was statistically significant ($P = .04$). In the differential anterior chamber depth map, the highest postoperative anterior chamber depth reduction matched the exact position of the cone apex, the thinnest point, and the greatest corneal flattening.

As seen from the data in **Table 6**, Ambrósio indices decreased except for the minimum sagittal curvature, which increased significantly ($P = .02$) from baseline to 24 months after CXL.

ENDOTHELIAL CELL COUNT

The mean baseline endothelial cell count was 2651/mm² (321/mm²). One month after the procedure, it was 2485/mm² (600/mm²); 3 months after, 2390/mm² (625/mm²); 6 months after, 2512/mm² (587/mm²); 12 months after, 2598/mm² (564/mm²); and 24-month values, 2520/mm² (523/mm²). The difference between the baseline and

Table 6. Changes in Ambrósio Indices Measured With Optical Tomography Using the Scheimpflug Camera

Index	Pre-CXL	24-mo Follow-up
Surface variance	113.80	103.67 ^{b,c}
Vertical asymmetry	1.28	1.23 ^b
Keratoconus	1.31	1.03 ^{b,c}
Center keratoconus	1.07	1.06 ^b
Height asymmetry, μm	36.17	24.77 ^{b,c}
Height decentration, mm	0.11	0.10 ^b
Minimum sagittal curvature, mm	5.81	6.21 ^{b,d}
Aberration coefficient, RMS	2.78	2.40 ^{b,c}

Abbreviations: CXL, corneal collagen cross-linking; RMS, root mean square.

^aPerformed using the Pentacam HR scanner (Oculus Inc, Lynnwood, Washington).

^bIndicates decreased values at the 24-month follow-up examination.

^cIndicates statistically significant differences for the 24-month follow-up examination, calculated using the paired *t* test for dependent data.

^dIndicates increased values at the 24-month follow-up examination.

24 months after the procedure was not statistically significant ($P = .13$), indicating that CXL did not induce endothelial damage during follow-up.

No ocular or systemic adverse events were observed, and no significant intraocular pressure changes were seen.

COMMENT

To the best of our knowledge, this is the first study in which intraoperative topographic changes during the CXL procedure and post-CXL refractive, topographic, tomographic, and aberrometric outcomes have been analyzed in eyes with progressive stage III keratoconus.

Intraoperative topographic analysis of eyes undergoing CXL produced insight into the role of the epithelium in affecting total corneal power³⁴ and masking the true curvature of keratoconic corneas.³⁵⁻³⁸ Intraoperative topography obtained after epithelial removal showed a dramatic change in corneal power with an increase in the steepest meridian keratometry, simulated cylinder, and apical keratometry immediately after epithelial abrasion (**Figure**, A, B, and D). Instantaneous maps demonstrated that each cone is surrounded by a ring-shaped flat area. A comparison of the flattest point of the anterior surface curvature before and after epithelial debridement showed a significant mean change from 36.44 to 32.77 D, suggesting that the epithelium probably fills in the "valleys" around the cone and would therefore be thicker where the stroma is flatter. In contrast, a comparison of instantaneous maps of the steepest point of the anterior surface curvature before and after epithelial abrasion showed a mean change from 58.82 to 61.05 D. This difference could be caused by a thinner epithelium at the cone apex, where the stroma is steeper.

The curvature changes observed are consistent with several histologic studies performed with light,³⁹⁻⁴¹ transmission electron,⁴² and scanning electron⁴³ microscopy, which demonstrate an overall thinning of the epithelium across the keratoconic cornea and an apparent variation in epithelial thickness with a thinning in the central region and

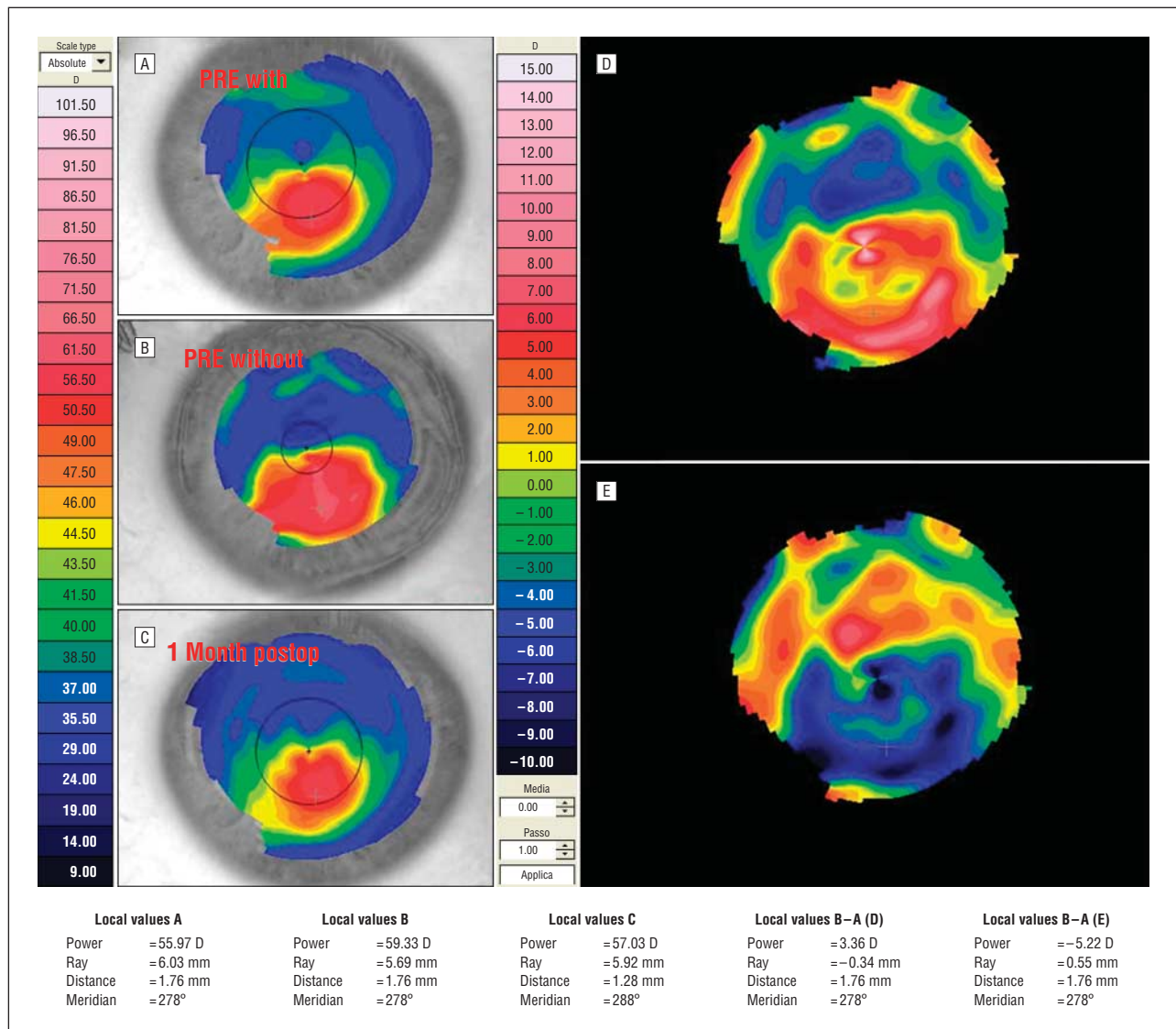


Figure. Results of corneal topography in the left eye of a patient performed with a corneal topography device (CSO EyeTop Topographer; Compagnia Strumenti Oftalmici, Florence, Italy). A, Topographic instantaneous map before epithelial scraping (PRE with). B, Topographic instantaneous map immediately after epithelial scraping (PRE without). C, Topographic instantaneous map after UV-A irradiation (1 month postop). D, Differential instantaneous map of B minus A. E, Differential instantaneous map of C minus B. D indicates diopter.

a thickening toward the inferior keratoconic cornea. Optical coherence tomography⁴⁴ and very-high-frequency digital ultrasound arc-scanning technology (described by Reinstei⁴⁵) showed that the epithelium is always thinner at the cone apex. In our study, the intraoperative findings indicate that the epithelium acts as a smoothing agent that reduces corneal power, astigmatism, and irregularity of keratoconic corneas.⁴⁶⁻⁵⁰

This finding explains why topography obtained 1 month after CXL paradoxically shows an increase in the steepness of the cone. Instead of an effect of the CXL procedure itself, the increase results from the epithelial debridement alone. After reepithelialization, the effect of CXL in flattening and regularizing the keratoconic shape of the cornea is not evident until 6 months after the procedure.

However, the comparison of the intraoperative topography performed immediately after epithelial scraping (ie, before CXL) with the topography obtained 1 month post-

operatively showed that the procedure had a significant effect in flattening and regularizing the corneal curvature (Figure, E). Instantaneous map comparisons of the steepest point of the anterior surface curvature after epithelial abrasion and 1 month postoperatively showed a mean change from 61.05 to 60.54 D; the flattest point of anterior surface curvature changed from 32.77 to 34.12 D. The keratoconus regressed after CXL with flattening at the steepest point measuring an average of 11 μ m after the procedure and the flat area surrounding the cone becoming progressively steeper, thus regularizing corneal curvature and reducing superior-inferior asymmetry.

Long-term follow-up showed that, after initial worsening of all keratoconus indices because of epithelial debridement, the indices improved slowly but continuously for 24 months postoperatively. This improvement was probably due to reepithelialization and the remodeling effect of CXL (Tables 3 and 4). Planned studies with optical coherence tomography and very-high-frequency digital ultrasound arc-

scanning units may supply more data on the redistribution of the epithelium over the corneal surface after CXL.

Corneal collagen cross-linking resulted in corneal flattening with a significant improvement in uncorrected and best spectacle-corrected VA 24 months postoperatively. At this point, 12 patients had gained 1 line of uncorrected VA and 15 had gained 2 lines of best spectacle-corrected VA. Mean refraction showed a statistically significant decrease in sphere and cylinder ($P=.03$) and a shift in axis ($P=.64$) after CXL. The keratometry readings decreased, as did corneal asymmetry, defocus, and astigmatic, coma, and spherical aberrations.

The significant reduction of simulated keratometry, average pupillary power, apical keratometry, apical gradient curvature, inferior-superior index, cone area, corneal aberrations, and the Klyce and Ambrósio indices explain the improvement in postoperative VA. Similar results were noted by Caporossi et al⁸ and Wollensak et al.¹ Both groups showed a postoperative decrease in mean keratometry and a reduction of manifest spherical equivalent. We conclude that the refractive outcomes were achieved by a flattening of the cone apex and a steepening of the part of the cornea symmetrically opposite the cone.

Corneal surface aberrometric analysis showed an improvement in all of the corneal aberrations to the seventh order, indicating a significant change in the anterior surface of the cornea. The Klyce topographic and Ambrósio tomographic indices confirmed a keratoconus regression after CXL. The Klyce indices of the treated eyes had significantly decreased by 24 months after CXL, whereas the untreated eyes showed significantly higher Klyce indices by the end of follow-up.

In conclusion, we found no statistically significant difference in corneal endothelial cell counts when comparing the preoperative and 24-month measurements, a finding supported by Wollensak et al.^{5,6,51,52} The lack of evidence of endothelial cell loss is an important safety consideration in assessing this new procedure. Follow-up in this patient cohort was not long enough to assess the long-term effectiveness of CXL. However, the results appear promising.

Submitted for Publication: August 19, 2008; final revision received December 29, 2008; accepted January 19, 2009.

Correspondence: Paolo Vinciguerra, MD, Department of Ophthalmology, Istituto Clinico Humanitas, Via Manzoni 56, Rozzano 20089, Milan, Italy.

Financial Disclosure: None reported.

REFERENCES

1. Wollensak G, Spoerl E, Seiler T. Riboflavin/ultraviolet-A-induced collagen crosslinking for the treatment of keratoconus. *Am J Ophthalmol*. 2003;135(5):620-627.
2. Wollensak G, Spörl E, Seiler T. Treatment of keratoconus by collagen cross linking [in German]. *Ophthalmologie*. 2003;100(1):44-49.
3. Wollensak G. Crosslinking treatment of progressive keratoconus: new hope. *Curr Opin Ophthalmol*. 2006;17(4):356-360.
4. Hayes S, O'Brart DP, Lamdin LS, et al. Effect of complete epithelial debridement before riboflavin-ultraviolet-A corneal collagen crosslinking therapy. *J Cataract Refract Surg*. 2008;34(4):657-661.
5. Wollensak G, Spoerl E, Seiler T. Stress-strain measurements of human and porcine corneas after riboflavin-ultraviolet-A-induced cross-linking. *J Cataract Refract Surg*. 2003;29(9):1780-1785.
6. Wollensak G, Wilsch M, Spoerl E, Seiler T. Collagen fiber diameter in the rabbit cornea after collagen crosslinking by riboflavin/UVA. *Cornea*. 2004;23(5):503-507.
7. Wollensak G, Iomdina E. Long-term biomechanical properties of rabbit cornea after photodynamic collagen crosslinking. *Acta Ophthalmol*. 2009;87(1):48-51.
8. Caporossi A, Baiocchi S, Mazzotta C, Traversi C, Caporossi T. Parasurgical therapy for keratoconus by riboflavin-ultraviolet type A rays induced cross-linking of corneal collagen: preliminary refractive results in an Italian study. *J Cataract Refract Surg*. 2006;32(5):837-845.
9. Maguire LJ, Lowry JC. Identifying progression of subclinical keratoconus by serial topography analysis. *Am J Ophthalmol*. 1991;112(1):41-45.
10. Lovisolo CF, Calossi A, Ottone AC. Intrastromal inserts in keratoconus and ectatic corneal conditions. In: Lovisolo CF, Fleming JF, Pesando PM, eds. *Intrastromal Corneal Ring Segments*. Canelli, Italy: Fabiano Editore; 2000:95-163.
11. Alió JL, Shabayek MH. Corneal higher order aberrations: a method to grade keratoconus. *J Refract Surg*. 2006;22(6):539-545.
12. Lim L, Wei RH, Chan WK, Tan DT. Evaluation of higher order ocular aberrations in patients with keratoconus. *J Refract Surg*. 2007;23(8):825-828.
13. Jafri B, Li X, Yang H, Rabinowitz YS. Higher order wavefront aberrations and topography in early and suspected keratoconus. *J Refract Surg*. 2007;23(8):774-781.
14. Spoerl E, Mrochen M, Sliney D, Trokel S, Seiler T. Safety of UVA-riboflavin cross-linking of the cornea. *Cornea*. 2007;26(4):385-389.
15. Spoerl E, Huhle M, Seiler T. Induction of cross-links in corneal tissue. *Exp Eye Res*. 1998;66(1):97-103.
16. Spoerl E, Seiler T. Techniques for stiffening the cornea. *J Refract Surg*. 1999;15(6):711-713.
17. Spoerl E, Wollensak G, Seiler T. Increased resistance of crosslinked cornea against enzymatic digestion. *Curr Eye Res*. 2004;29(1):35-40.
18. Bailey IL, Lovie JE. New design principles for visual acuity letter charts. *Am J Optom Physiol Opt*. 1976;53(11):740-745.
19. Committee on Vision, Assembly of Behavioral and Social Sciences, National Academy of Sciences-National Research Council, National Academy of Sciences, Washington, DC. Recommended standard procedures for the clinical measurement and specification of visual acuity: report of Working Group 39. *Adv Ophthalmol*. 1980;41:103-148.
20. Ferris FL III, Kassoff A, Bresnick GH, Bailey I. New visual acuity charts for clinical research. *Am J Ophthalmol*. 1982;94(1):91-96.
21. Calossi A. Le altimetrie corneali con sistemi a disco di Placido. In: Mularoni A, Tassinari G, eds. *La Topografia Altitudinale*. Canelli, Italy: Fabiano Editore; 2005:136-139.
22. Smolek MK, Klyce SD. Current keratoconus detection methods compared with a neural network approach. *Invest Ophthalmol Vis Sci*. 1997;38(11):2290-2299.
23. Maeda N, Klyce SD, Smolek MK. Comparison of methods for detecting keratoconus using videokeratography. *Arch Ophthalmol*. 1995;113(7):870-874.
24. Maeda N, Klyce SD, Smolek MK, Thompson HW. Automated keratoconus screening with corneal topography analysis. *Invest Ophthalmol Vis Sci*. 1994;35(6):2749-2757.
25. Smolek MK, Klyce SD. Zernike polynomial fitting fails to represent all visually significant corneal aberrations. *Invest Ophthalmol Vis Sci*. 2003;44(11):4676-4681.
26. de Sanctis U, Loiacono C, Richiardi L, Turco D, Mutani B, Grignolo FM. Sensitivity and specificity of posterior corneal elevation measured by Pentacam in discriminating keratoconus/subclinical keratoconus. *Ophthalmology*. 2008;115(9):1534-1539.
27. de Sanctis U, Missolungi A, Mutani B, Richiardi L, Grignolo FM. Reproducibility and repeatability of central corneal thickness measurement in keratoconus using the rotating Scheimpflug camera and ultrasound pachymetry. *Am J Ophthalmol*. 2007;144(5):712-718.
28. Ho JD, Tsai CY, Tsai RJ, Kuo LL, Tsai IL, Liou SW. Validity of the keratometric index: evaluation by the Pentacam rotating Scheimpflug camera. *J Cataract Refract Surg*. 2008;34(1):137-145.
29. Shankar H, Taranath D, Santhirathelagan CT, Pesudovs K. Anterior segment biometry with the Pentacam: comprehensive assessment of repeatability of automated measurements. *J Cataract Refract Surg*. 2008;34(1):103-113.
30. Al-Mezaine HS, Al-Amro SA, Kangave D, Sadaawy A, Wehaib TA, Al-Obeidan S. Comparison between central corneal thickness measurements by Oculus Pentacam and ultrasonic pachymetry. *Int Ophthalmol*. 2008;28(5):333-338.
31. Ambrósio R Jr, Alonso RS, Luz A, Coca Velarde LG. Corneal-thickness spatial profile and corneal-volume distribution: tomographic indices to detect keratoconus. *J Cataract Refract Surg*. 2006;32(11):1851-1859.

32. Prinz A, Varga J, Findl O. Reliability of a video-based noncontact specular microscope for assessing the corneal endothelium. *Cornea*. 2007;26(8):924-929.
33. Torres Munoz I, Grizzi F, Russo C, Camesasca FI, Dioguardi N, Vinciguerra P. The role of amino acids in corneal stromal healing: a method for evaluating cellular density and extracellular matrix distribution. *J Refract Surg*. 2003;19(2)(suppl):S227-S230.
34. Reinstein DZ, Archer TJ, Gobbe M, Silverman RH, Coleman DJ. Epithelial thickness in the normal cornea: three-dimensional display with Artemis very high-frequency digital ultrasound. *J Refract Surg*. 2008;24(6):571-581.
35. Vinciguerra P, Epstein D, Albè E, et al. Corneal topography-guided penetrating keratoplasty and suture adjustment: new approach for astigmatism control. *Cornea*. 2007;26(6):675-682.
36. Vinciguerra P, Munoz MI, Camesasca FI, Grizzi F, Roberts C. Long-term follow-up of ultrathin corneas after surface retreatment with phototherapeutic keratectomy. *J Cataract Refract Surg*. 2005;31(1):82-87.
37. Vinciguerra P, Camesasca FI. Custom phototherapeutic keratectomy with intraoperative topography. *J Refract Surg*. 2004;20(5)(suppl):S555-S563.
38. Vinciguerra P, Camesasca FI. One-year follow-up of custom phototherapeutic keratectomy. *J Refract Surg*. 2004;20(5)(suppl):S705-S710.
39. Efron N, Hollingsworth JG. New perspectives on keratoconus as revealed by corneal confocal microscopy. *Clin Exp Optom*. 2008;91(1):34-55.
40. Hollingsworth JG, Bonshek RE, Efron N. Correlation of the appearance of the keratoconic cornea in vivo by confocal microscopy and in vitro by light microscopy. *Cornea*. 2005;24(4):397-405.
41. Scroggs MW, Proia AD. Histopathological variation in keratoconus. *Cornea*. 1992; 11(6):553-559.
42. Aktekin M, Sargon MF, Cakar P, Celik HH, Firat E. Ultrastructure of the cornea epithelium in keratoconus. *Okajimas Folia Anat Jpn*. 1998;75(1):45-53.
43. Jongebloed WL, Worst JF. The keratoconus epithelium studied by SEM. *Doc Ophthalmol*. 1987;67(1-2):171-181.
44. Haque S, Simpson T, Jones L. Corneal and epithelial thickness in keratoconus: a comparison of ultrasonic pachymetry, Orbscan II, and optical coherence tomography. *J Refract Surg*. 2006;22(5):486-493.
45. Reinstein DZ. Subsurface screening for keratoconus. *Cataract Refract Surg Today*. May 2007:88-89.
46. Simon G, Ren Q, Kervick GN, Parel JM. Optics of the corneal epithelium. *Refract Corneal Surg*. 1993;9(1):42-50.
47. Patel S, Reinstein DZ, Silverman RH, Coleman DJ. The shape of Bowman's layer in the human cornea. *J Refract Surg*. 1998;14(6):636-640.
48. Gatinel D, Racine L, Hoang-Xuan T. Contribution of the corneal epithelium to anterior corneal topography in patients having myopic photorefractive keratectomy. *J Cataract Refract Surg*. 2007;33(11):1860-1865.
49. Emre S, Doganay S, Yologlu S. Evaluation of anterior segment parameters in keratoconic eyes measured with the Pentacam system. *J Cataract Refract Surg*. 2007; 33(10):1708-1712.
50. Mencucci R, Mazzotta C, Rossi F, et al. Riboflavin and ultraviolet A collagen crosslinking: in vivo thermographic analysis of the corneal surface. *J Cataract Refract Surg*. 2007;33(6):1005-1008.
51. Wollensak G, Spoerl E, Wilsch M, Seiler T. Endothelial cell damage after riboflavin-ultraviolet-A treatment in the rabbit. *J Cataract Refract Surg*. 2003;29(9):1786-1790.
52. Wollensak G, Spoerl E, Reber F, Seiler T. Keratocyte cytotoxicity of riboflavin/UVA-treatment in vitro. *Eye*. 2004;18(7):718-722.

Correction

Errors in Author Byline. In the Clinical Sciences article titled "Further Insight Into West African Crystalline Maculopathy," published in the July 2009 issue of the *Archives* (2009;127[7]:863-868), the author byline was ordered incorrectly and Dr Mohamed's academic honors were incomplete. The byline should have read Saul N. Rajak, MRCOphth; Lucia Pelosini, MRCOphth, MRCSEd; Moin D. Mohamed, PhD, FRCS, FRCOphth.