



Howard F. Fine
Practical Retina
Co-editor

The art of managing wet AMD involves maximizing visual outcome while minimizing treatment burden. Drs. K. Bailey Freund and Michael Engelbert from New York share their insights on this complex topic in this column.

Interestingly, while their group first popularized the treat-and-extend approach, which has become the most common choice by U.S. retina specialists for managing wet AMD, randomized controlled trials employing this paradigm are just beginning to emerge.

More than a decade has passed since the dawn of the anti-VEGF era in retina, and we still grapple with the optimal dosing strategy in wet AMD. By harnessing the power of multimodal imaging and a revised classification for the anatomic location of the choroidal neovascularization in wet AMD, Drs. Freund and Engelbert provide a rational algorithm, more refined and nuanced than the traditional treat-and-extend approach, that will be of great interest to the retina community.

Individualizing the intravitreal anti-VEGF dosing regimen for long-term management of neovascular AMD

by K. Bailey Freund, MD, and Michael Engelbert, MD, PhD

While anti-vascular endothelial growth factor (VEGF) therapy affords patients with neovascular age-related macular degeneration (AMD) a dramatically improved prognosis compared to all prior treatments, the chronic nature of the disease and the uncertainties regarding long-term dosing strategies represent important therapeutic challenges.

Large randomized trials established the efficacy and safety of ranibizumab, bevacizumab, and aflibercept for the treatment of neovascular AMD, yet these studies offered little insight into the optimal dosing regimen for individual patients or how to manage patients after 2 years of intensive therapy. Unfortunately, the data regarding long-term outcomes for anti-VEGF therapy suggest that deviations from close monitoring and/or injections, even after 2 years, will likely result in an accelerated rate of vision loss in many eyes.¹



K. Bailey Freund



Michael Engelbert

Long-term anti-VEGF maintenance challenges the practitioner with identifying the appropriate interval between office visits and injections for each individual patient that minimizes recurrences while also reducing the treatment burden and risks of treatment-related complications. A desire to individualize treatment and an early recognition of the long-term treatment challenges led to our adoption of a treat-and-extend regimen to manage the majority of our patients with neovascular AMD.² Despite a lack of level 1 evidence to support the efficacy and long-term safety of a treat-and-extend regimen, this dosing strategy has become the most popular among U.S. retinal specialists.³

While most studies have shown better visual outcomes with more frequent injections, clinicians must now consider data from three large, randomized anti-VEGF trials all suggesting that more frequent dosing of anti-VEGF therapy for neovascular AMD may be associated with a more rapid progression of geographic atrophy (GA). These data raise new concerns that overtreatment may accelerate GA in some eyes.⁴⁻⁶

In our practice, we rely on a more refined analysis of baseline neovascular lesion composition in a shift from our previously described treat-and-extend regimen to a more individualized dosing regi-

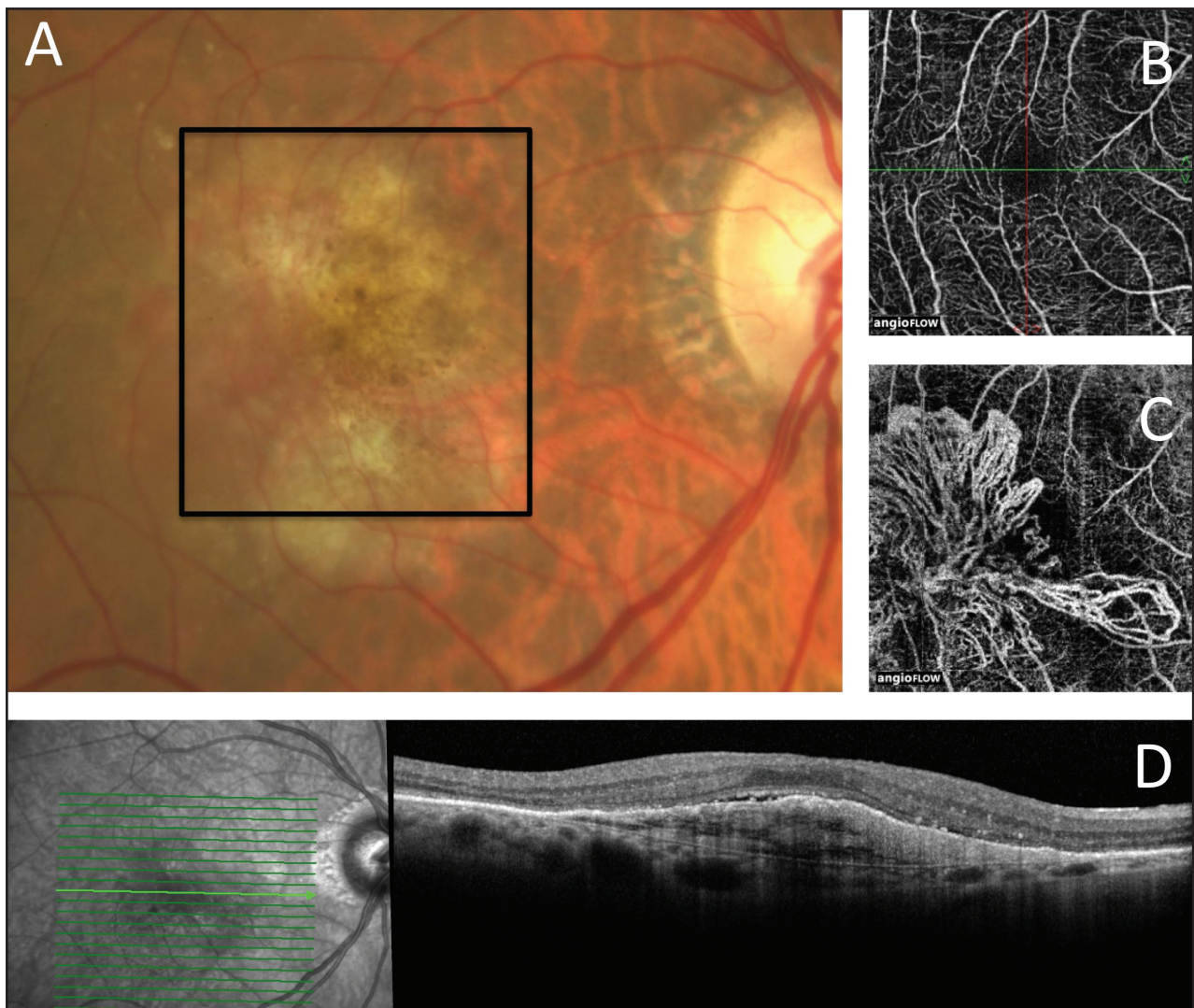


Figure 1. (A) Color photograph shows the right eye of an 82-year-old woman with neovascular age-related macular degeneration after 68 intravitreal anti-VEGF injections at intervals of approximately every 5 to 6 weeks. Visual acuity is 20/50. (B) En face OCT angiography at the level of the inner retina shows a normal retinal vascular pattern. (C) En face OCT angiography segmenting just below the retinal pigment epithelium shows an extensive tangled network of mature type 1 neovessels. (D) SD-OCT shows type 1 neovascularization with a small amount of overlying subretinal fluid and fairly well preserved outer retinal architecture.

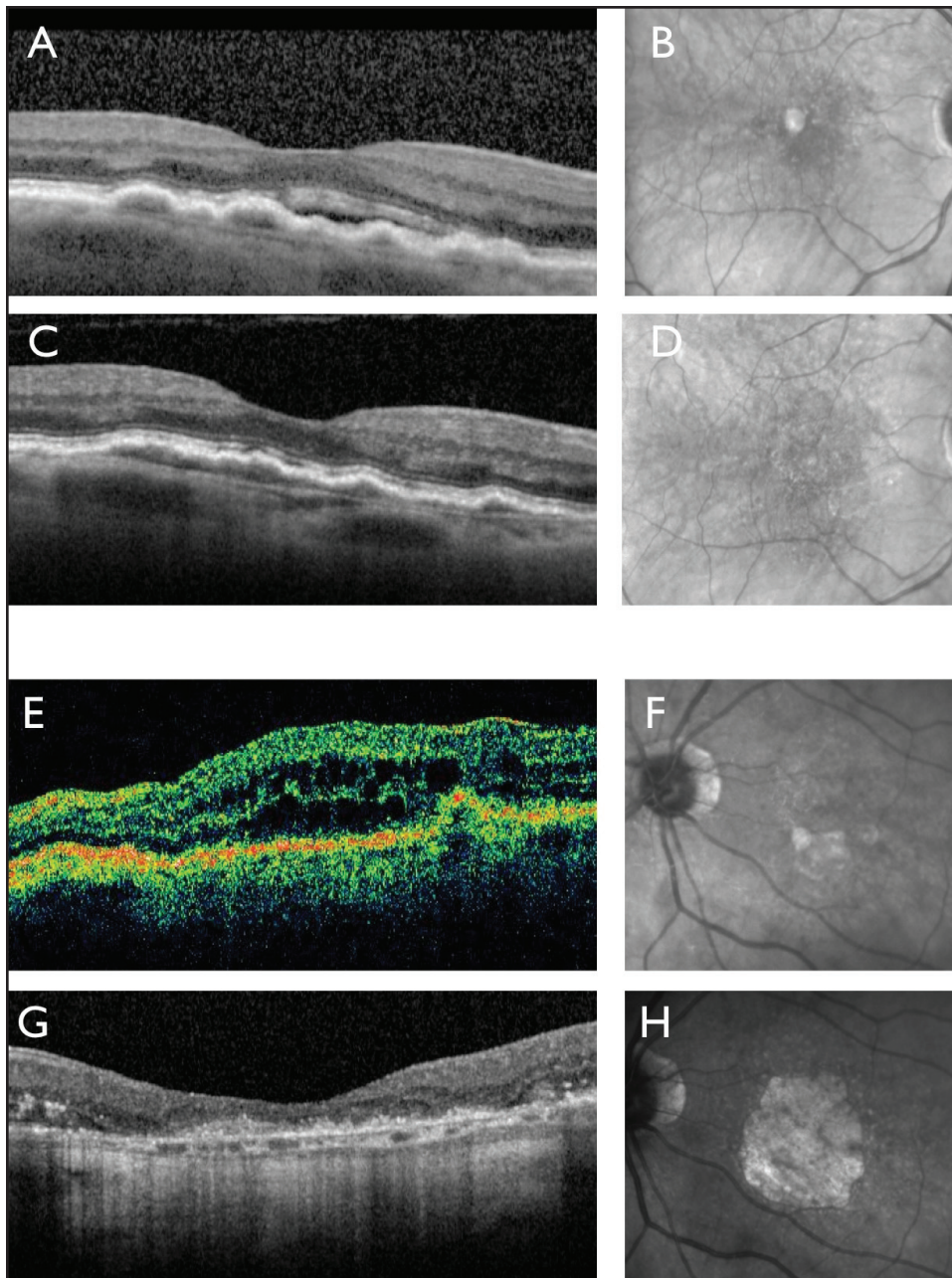


Figure 2. SD-OCT (A) and near-infrared reflectance (NIR) image (B) show the right eye of an 80-year-old woman with newly symptomatic type 1 neovascularization. A treat-and-extend regimen with a 4- to 6-week injection interval was initiated. SD-OCT (C) and NIR image (D) 5 years later and after 41 intravitreal injections of ranibizumab show persistence of type 1 neovascularization but no evidence of geographic atrophy. Vision remains stable at 20/50. Time-domain OCT (E) and NIR image (F) show the left eye of an 87-year-old man with newly symptomatic type 3 neovascularization. A treat-and-extend regimen with a 5- to 6-week injection interval was initiated. SD-OCT (G) and NIR image (H) 5 years later and after 45 intravitreal injections of ranibizumab show extensive geographic atrophy. Vision has deteriorated to 20/400.

men for each eye of each treated patient. The foundation of this approach is the consistent use of an anatomic classification of neovascular lesion type first suggested by Grossniklaus and Gass⁷ that we have expanded to incorporate the findings of both angiography and OCT in determining the location of the neovascular tissue with respect to the retinal layers.⁸ Type 1 lesions are located below the retinal pigment epithelium (RPE), whereas type 2 lesions occur in the subretinal space. Type 3 lesions, often referred to as retinal angiomatous proliferation, or RAP, are predominantly intraretinal but often con-

nect to deeper type 1 neovascularization as they mature. We consider polypoidal choroidal vasculopathy a form of type 1 neovascularization because the polyps arise from a type 1 neovascular complex that typically represents a larger proportion of the entire lesion than the polyps themselves.

In our experience, eyes with type 1 lesions show considerable variability in their sensitivity to anti-VEGF therapy. Some of these eyes will harbor large mature neovessels. OCT angiography is a new imaging tool (not currently FDA-approved) that helps to clearly identify these larger vessels (Figure 1).

These mature vessels may produce recalcitrant exudation manifested as persistent subretinal fluid, often despite monthly treatment. Interestingly, these eyes often maintain excellent vision despite the discouraging presence of persistent fluid, but the large vessels within the lesion pose a risk for large hemorrhages, particularly when polypoidal choroidal vasculopathy is present. Despite the refractory nature of type 1 lesions, our long-term data show that eyes with type 1 lesions maintain good vision longer than eyes with any of the other lesion subtypes and are by far the least susceptible to long-term GA (Figures 2A-D).⁹ We typically use a maintenance treat-and-extend regimen in eyes with type 1 lesions, because we are less concerned about GA than the potential for catastrophic macular hemorrhage. We will often tolerate small amounts of subretinal fluid, even when it is subfoveal in location. Pure type 2 lesions are rather uncommon in typical neovascular AMD, occurring in only 9% (24 of 266) of newly diagnosed eyes in our recently reported series.⁹ Early in their course, these lesions are very sensitive to anti-VEGF therapy, but as the lesions evolve into more mature fibrous tissue, resistance to treatment and early recurrences are more common. The location of the neovascular tissue directly beneath the photoreceptors, manifested as subretinal hyperreflective material on OCT, makes these lesions particularly prone to producing irreversible retinal damage. When OCT shows disruptions in the outer retinal anatomy overlying type 2 lesions, refractory intraretinal fluid is often seen. We believe that in many cases, this fluid represents the manifestation of outer retinal damage causing poor vision but is not its underlying cause. We often avoid aggressive treatment of this finding, because it is unlikely to benefit eyes in which irreversible photoreceptor damage has already occurred. The decision to continue a treat-and-extend regimen or switch to an as-needed regimen will depend on many factors including visual potential in both the treated and fellow eye, prior history of recurrent exudation with interval extensions, size and proximity of the lesion to the fovea, and whether the patient is undergoing anticoagulation therapy.

When evaluated by experienced graders, type 3 lesions are far more common than previously recognized, occurring in 34.2% of (91 of 266) newly diagnosed neovascular AMD cases in our recent series.¹⁰ OCT can be very helpful in the detection of these lesions, as can OCT angiography, when put to clinical use. Early type 3 lesions can be exquisitely sensitive to anti-VEGF therapy showing complete regression, while more mature type 3 lesions presenting with serous pigment epithelial detachments

indicative of anastomoses to type 1 neovascular tissue will typically show early recurrence of fluid following extensions of the dosing interval. When type 3 lesions recur, there is typically minimal or no hemorrhage, so the risk of irreversible vision loss is minimal. Also, because eyes with type 3 lesions appear to be at high risk for the development of GA (Figures 2E-H), we believe that attempting an as-needed dosing regimen in these eyes is appropriate. This particular susceptibility is likely related to the occurrence of type 3 lesions in eyes with risk factors for GA including thin choroids and reticular pseudodrusen.¹¹ If exudation recurs frequently in eyes with type 3 lesions, we will typically revert back to a treat-and-extend regimen with the longest interval that still maintains minimal fluid.

In most patients treated according to a treat-and-extend regimen, we do not extend the treatment interval beyond 10 to 12 weeks due to our concern for sight-threatening submacular hemorrhages. When using an as-needed approach, we typically monitor patients monthly for at least 6 to 12 months before extending the interval between examinations. Deciding when it is safe to extend the monitoring interval remains one of the greatest challenges in the long-term management of these patients. While intuitively it might seem that the long periods of disease quiescence would be predictive of a reduced risk for recurrent exudation in the future, unfortunately we have found that this is often not the case.

In summary, the long-term management of neovascular AMD with intravitreal anti-VEGF therapy presents retinal specialists with numerous challenges. As described above, we have found the use of an anatomic classification of baseline lesions based on multimodal imaging helps us to individualize dosing regimens for each patient. We believe that this personalized strategy leads to better visual outcomes by achieving a better balance of risk and benefits compared to a “one size fits all” approach to this complicated disease.

REFERENCES

1. Rofagha S, Bhisitkul RB, Boyer DS, Sadda SR, Zhang K. Seven-year outcomes in ranibizumab-treated patients in ANCHOR, MARINA, and HORIZON: A multicenter cohort study (SEVEN-UP). *Ophthalmology*. 2013;120:2292-2299.
2. Engelbert M, Zweifel SA, Freund KB. “Treat and extend” dosing of intravitreal anti-vascular endothelial growth factor therapy for type 3 neovascularization/retinal angiomatous proliferation. *Retina*. 2009;29:1424-1431.
3. Stone TW, ed. ASRS 2014 Preferences and Trends Membership Survey. Chicago, IL; American Society of Retina Specialists; 2014.
4. Grunwald JE, Daniel E, Huang J, et al. Risk of geographic atrophy in the comparison of age-related macular degeneration treatments trial.

Ophthalmology. 2014;121(1):150-161.

5. Chakravarthy U, Harding SP, Rogers CA, et al. Alternative treatments to inhibit VEGF in age-related choroidal neovascularization: 2-year findings of the IVAN randomized controlled trial. *Lancet*. 2013;382:1258-1267.
6. Sadda SR. Development of atrophy in neovascular AMD treated with anti-VEGF therapy: Results of the HARBOR Study. AAO Retina Subspecialty Day 2014, Chicago, IL.
7. Grossniklaus HE, Gass JD. Clinicopathologic correlations of surgically excised type 1 and type 2 submacular choroidal neovascular membranes. *Am J Ophthalmol*. 1998;126(1):59-69.
8. Freund KB, Zweifel SA, Engelbert M. Do we need a new classification for choroidal neovascularization in age-related macular degeneration? *Retina*. 2010;30:1333-1349.
9. Xu L, Mrejen S, Jung JJ, et al. Geographic atrophy in patients receiving anti-vascular endothelial growth factor for neovascular age-related macular degeneration. *Retina*. 2015;35(2):176-186.
10. Jung JJ, Chen CY, Mrejen S, et al. The incidence of neovascular subtypes in newly diagnosed neovascular age-related macular degeneration. *Am J Ophthalmol*. 2014;158(4):769-779.
11. Marcela M, Boddu S, Chen C, et al. Correlation between neovascular lesion type and clinical characteristics of non-neovascular fellow eyes in patients with unilateral neovascular age-related macular degeneration. *Retina*. 2015;35(5):966-974.

K. Bailey Freund, MD, can be reached at Vitreous Retina Macula Consultants of New York, 460 Park Avenue, 5th Floor, New York, NY 10022; 212-861-9797; fax: 212-628-0698; email: kbfnfy@aol.com.

Michael Engelbert, MD, PhD, can be reached at Vitreous Retina Macula Consultants of New York, 460 Park Avenue, 5th Floor, New York, NY 10022; 212-861-9797; fax: 212-628-0698; email: michael.engelbert@gmail.com.

Howard F. Fine, MD, MHSc, can be reached at at NJ Retina, 10 Plum Street, Suite 600, New Brunswick, NJ 08901; 732-220-1600; fax: 732-220-1603; email: hffne@gmail.com.

Disclosures: Dr. Freund is a consultant for Genentech, Optovue, Heidelberg Engineering, ThromboGenics, and Ohr Pharmaceutical. Dr. Engelbert is a consultant for Genentech and Bayer. Dr. Fine has received research grants, consulting fees, and/or is on the speakers bureau for Allergan/Actavis, Genentech, and Regeneron. He has equity, patent, and consulting interests in Auris Surgical Robotics.